

PROUD TO BE AN INDEPENDENT EQUINE PRACTICE OWNED BY VETS

HEAD OFFICE: 64 FORE STREET, NORTH TAWTON, DEVON, EX20 2DT

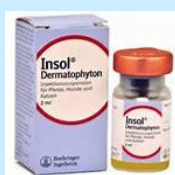MEDICATION COLLECTION POINTS: OKEHAMPTON, HATHERLEIGH AND HOLSWORTHY

EQUUS VETS NEWSLETTER JANUARY 2025

PRACTICE NEWS

We are very aware that the cost of living is ever increasing. The Equus team are very mindful of this and regularly look at the best drug deals out there so that we can pass the benefit of the deal on to our clients. There will be upcoming changes to the brand name of products dispensed but the constitution of the drug will remain the same.

The point to point season is fast approaching so Hayden will be preparing to be Senior Duty Vet at lots of the local point to points. Hayden is a member of the ARVS (Association of Racehorse veterinary surgeons) who promote the safeguarding and safety of racehorses at race meetings.



INSOL INJECTION

*****DUE NOW*****



- Insol is an off-licence medication that is used to aid the management of sweet itch and is proven to help those that suffer with it.
- Insol is given as a preventative measure for sweet itch and we are coming up to the 'pre midge season' for horses and the required time for them to be given the treatment.
- It is recommended that horses are given two injections, two weeks apart at the end of January or in February.
- We order the drug in specifically so please call our reception team if you would like your horse to be added to the list and book an appointment or if you have any questions - 01837 214 004

SAM ON HIS TRAVELS IN DECEMBER



We are proud to share that Sam was asked to be one of the on call vets at the London International Horse Show at the Excel in December for all the horses competing in various competitions. Sam even managed to get a picture taken by the Puissance Wall and got given some down time to enjoy watching the show as well.



Providing you with a dedicated and experienced team of equine only vets, 24 hours a day, 7 days a week covering Devon and East Cornwall

01837 214004 – info@equusvets.co.uk



We have a range of high-tech portable equipment enabling us to provide diagnostics in the comfort of your own yard:

Digital x ray machines

Video Gastroscope

Video Endoscope

Ultrasound Machine

Oroscope for dental examinations and teeth rasping

In addition to the portable equipment, we can also offer:

In-house Laboratory facilities

Lameness examination and work ups

Acupuncture

Following on from our Colic, below is a Case Study that we have seen recently:

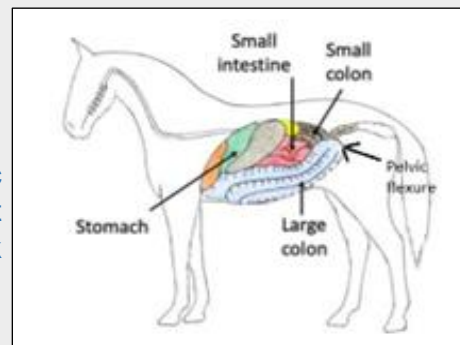
HISTORY

Perkins was found one morning rolling and kicking his abdomen. Recognising the signs of colic, his owner called us promptly.

Perkins had been stabled more and eating more hay over the preceding few days due to Storm Darragh. This, in combination with his teeth not being as good as they were in his younger days, lead to Perkins developing an impaction colic.

EXAMINATION & DIAGNOSIS

In Perkin's case, the impaction was diagnosed on rectal examination, where a hard mass of food material causing a blockage could be felt in the pelvic flexure – a point in the large intestine that simultaneously narrows and turns 180 degrees back on itself, making it a prime location for food material to get stuck!



TREATMENT PLAN

Perkins was treated with pain relief and fluids via a stomach tube. Fluids are important in impaction colics, as it rehydrates the dried-out food material that is causing the blockage and stimulates the guts to move, allowing the blockage to clear. After several visits, Perkins started drinking and stomach tubing was no longer required. Repeat rectal examinations allowed us to monitor his impaction, which cleared after 48 hours.

As Perkins' appetite returned, his owners noticed he was quidding a little. Dental examination revealed he had a loose tooth, which likely contributed to the development of the impaction as Perkins was probably not chewing his food properly. The offending tooth was duly removed under sedation.

PROGNOSIS

Following careful reintroduction of feed by his owners, Perkins was given the all-clear and allowed to return to his usual regime. We are delighted to report that Perkins has fully recovered and is doing well.



EAST CORNWALL AREA DAYS



*W/C 10th FEBRUARY
W/C 24th FEBRUARY*

!!SAVE THE DATE!!

CLIENT EVENING

Our next client evening is planned for the 12th March at 18.30 for a 19.00 start at Bridestowe Village Hall – more details to follow

Providing you with a dedicated and experienced team of equine only vets, 24 hours a day, 7 days a week covering Devon and East Cornwall

NORTH TAWTON – OKEHAMPTON – HATHERLEIGH - HOLSWORTHY

01837 214004 – info@equusvets.co.uk